Array Publishers
Open Journal of Case Reports
Case Report

Small Intestinal Lipoma: Case Report

Moussa Coulibaly*, Wariss Adegbindin, Ansoumane H Keita, Ayoub Elhajjami, Najat Cherif Idrissi Ganouni
Department of Radiology, CHU Mohammed VI, Cadi Ayad University, Marrakesh, Morocco

Corresponding author: Moussa Coulibaly, Department of Radiology, CHU Mohammed VI, Cadi Ayad University, Marrakesh, Morocco. Email: moussacoulby@gmail.com

Received Date: 04 March, 2023 ; **Accepted Date:** 08 March, 2023; **Published Date:** 13 March, 2023

Abstract

Lipomas of the Gastrointestinal Tract (GIT) are rare. Most submucosal lipomas of the GIT occur in the colon (65-75%), small intestine (25%), and rarely in the stomach or jejunum. These lesions are usually asymptomatic and are rarely discovered incidentally at autopsy.

Diagnosis is based mainly on CT scan. Only the histological study of the specimen can confirm it. We report a case of intestinal lipoma in a 58-year-old man admitted with paroxysmal abdominal pain and subocclusive syndrome for 4 days.

Keywords: Intestinal lipoma; CT scan; Negative density

Introduction

Lipomas of the Gastrointestinal Tract (GIT) are rare. They are usually asymptomatic. They occur in the 50-60 age range but can rarely occur at younger ages, and even more rarely in children [1].

They usually do not cause symptoms, but are only noticed when they cause intussusception, which leads to symptoms of obstruction such as pain, abdominal distension, and vomiting.

Computed Tomography (CT) usually confirms the diagnosis of intestinal lipomas. They usually occur in the large intestine, but rarely in the small intestine and stomach.

Case Report

A 58-year-old man, without any notable pathological history, was admitted to the emergency department with paroxysmal abdominal pain with subocclusive syndrome evolving for 4 days, without vomiting or rectorrhagia. The general condition was preserved, and he was apyretic.

On examination, there was slight distension of the abdomen which, on palpation, showed slight rigidity. Investigations, including complete blood count, hematocrit, and other routine laboratory tests were within normal limits.

An emergency abdominal CT scan was performed without and after contrast injection. It showed a mass in the submucosa of the small intestine, with dilatation of the gallbladder without an area of disparity in caliber (Figure 1)

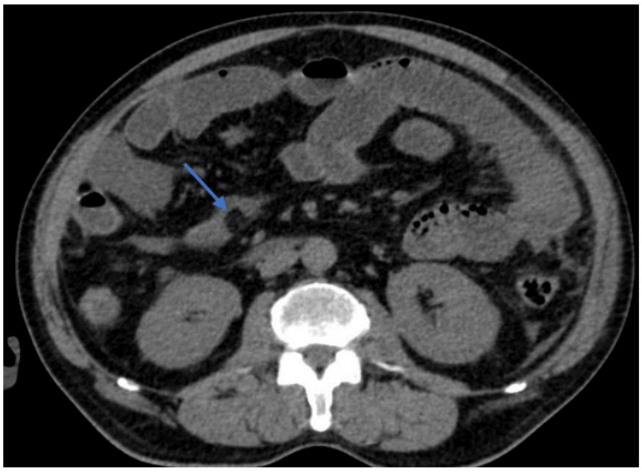

Figure 1: Injected abdominal CT: well-limited oval lesion, of fatty density (-80UH), without endo-lesional or wall enhancement: Lipoma of the small intestine (blue arrow).

Discussion

Lipomas are benign tumors formed by mature fat cells. They are very common mesenchymal tumors of unknown pathogenesis and ubiquitous location. Submucosal lipomas of the small intestine are rare and lipomas involving the muscle layer are even rarer. They are rarely seen during the first decade of life: less than 50 pediatric cases have been reported in the literature [2-5].

Imaging, especially CT scans, allows easy diagnosis, thanks to its characteristic appearance: a rounded or oval formation, with regular contours, negative density (-30 to 6100 HU), homogeneous, without contrast after injection of contrast medium. A thin capsule may be present [3].

The clinical manifestations of intestinal lipoma are variable. In addition to the latent forms discovered radiologically, endoscopically or surgically, painful, dyspeptic, hemorrhagic or sometimes obstructive pictures can be encountered depending on the volume and location of the lipoma [4].

Climie and Wylin [1], reported and described two cases of lipomatosis of the small intestine associated with intussusception.

A review by him reported 16 cases of intestinal lipomas. Neilson et al. [6], reported a case of simultaneous diverticulosis, lipomatosis, and volvulus of the small intestine.

Bodos et al. [7], reported a case of multiple lipomatosis involving the small and large intestine in a 10-year-old girl, causing obstructive symptoms. Philips and Svahn et al. [8], reported a case of colonic lipoma in a 54 year old person causing intussusception.

Conclusion

Although rare, intestinal lipomas are most often asymptomatic or revealed on the occasion of bowel obstruction. Therefore, such tumors should be considered clinically in the differential diagnosis of acute abdomen due to intussusceptions or intestinal obstruction. CT scan has its place in the positive diagnosis because of their fat content.

References

1. Climie AR, Wylin RF (1981) Small-intestinal lipomatosis. Arch Pathol Lab Med. 105: 40-42.
2. Kisra M, Ettayeby F, Zerhouni H, et al. (2005) Inte´re^t de la laparoscopie dans la prise en charge du lipome du me´sente`re. J Coelio Chir. 55: 75-77.
3. Heiken JP, Forde KA, Gold RP (1982) Computed tomography as a definitive method for diagnosting gastrointestinal lipomas. Radiology. 142: 409-414.
4. Yoshida T, Fujisaki J, Suganuma T, Kasuga A, Okada K, et al. (2012) Succefful en bloc resection of 5cm symptomatic sessile gastric lipoma by endoscopic submucosal dissection. Dic Endosc. 24: 282.
5. Sato M, Ishida A, Konno K, Komatsuda T, Naganuma H, et al. (2002) Mesenteric lipoma: report of a case with emphasis on US findings. Euro Radiol. 12: 640-642.

6. Neilson D, Wilkinson N, Magell J (1990) Case of simultaneous diverticulosis, lipomatosis and volvulus of the small intestine. Br J Surg. 77: 105.

7. Bodos A, Rivilla F, Maluenda C (2008) A 10 year old girl of multiple lipomatosis of small and large intestine. Eur J Paediatr. 5: 601.

8. Philips LJ 2nd, Svahn JD (2013) Colonic lipoma. A rare cause of adult intussusception. World J Colorectal Surg. 3: 19.